

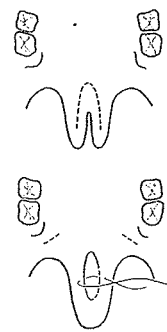
### *III. Lengthening the Palate*

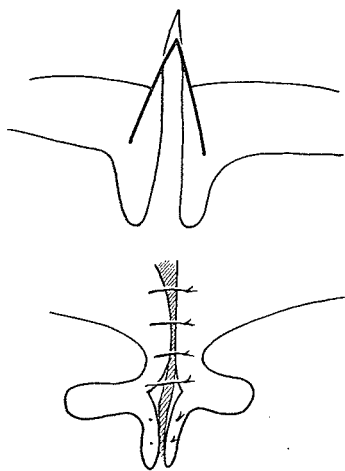
## 23. Lengthening of the Cleft Edges of the Uvula and Soft Palate

ONCE the sophistication of cleft palate surgery had advanced beyond merely closing the cleft hole, attention turned toward closure of the velopharyngeal aperture. Ingenious efforts were directed to surgical procedures which in various ways caused lengthening of some portion of the palate toward the posterior pharynx. These procedures of V-Y, transverse incisions closed vertically, angled releases and Z-plasties seemed to parallel in part some of the techniques used by lip surgeons to lengthen the short edges of the cleft labial elements. The first such effort is accredited to André Myrrhen in 1706. It is reported that he lengthened a soft palate by a method not described to compensate for a completely destroyed uvula and caused no damage to the patient's speech.

### LENGTHENING THE UVULA

In 1879 William S. Forbes of Philadelphia, while closing a cleft of the uvula, lengthened the velum by a curved incision which was a combination of V-Y and transverse incision closed vertically, similar to that used by Nélaton in incomplete lip clefts. This procedure undoubtedly created the longest uvulae in existence, whatever good that did!



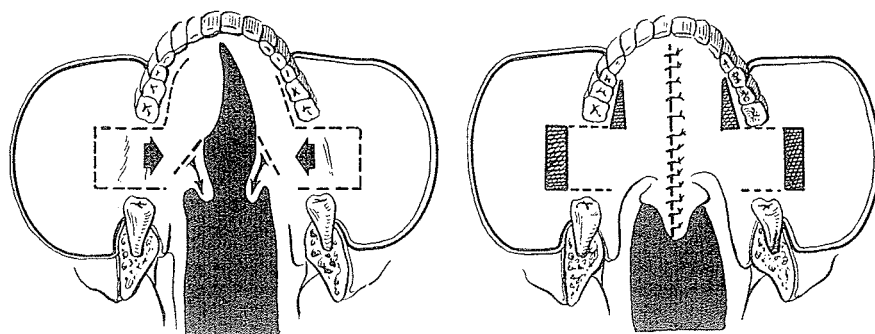


## K U E S T E R

The German E. Kuester attempted in 1882 to lengthen the velum with slanted lateral incisions in a V-Y type of principle similar to that used by Malgaigne in cleft lip. The result was a long, fascinating, trilobate uvula without improvement in function. Reverdin carried out a similar procedure in 1898.

## B L A I R

In 1911 Vilray Blair of St. Louis used angled releasing incisions to form triangular flaps of the velum, not unlike his later cleft lip flap, to achieve palate length. By advancing palatal mucoperiosteum and cheek mucosa medially, he was able to get lengthening of the palate without too great side-to-side tightness. As he said:



The cleft borders of the velum are [incised] . . . on either side through the whole thickness of the soft palate and the flaps behind these incisions are rotated backward. In this way, the incisions . . . are opened and the raw surfaces thus exposed are sutured to each other at the median line. . . . This operation gives a longer velum than is obtained by the simple Langenbeck operation and therefore a better functional result is obtained. It will not permanently cripple the action of the superior constrictor muscle of the pharynx.



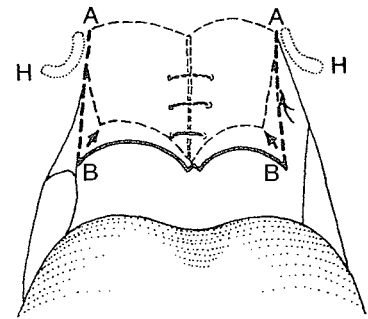
*Francis Mason*

## M A S O N

The most radical of the uvula-lengthening procedures was described in 1877 by Francis Mason of St. Thomas's Hospital and Kings College Hospital, London. As he still agreed with Passavant and Gustav Simon that nasal twang in speech was due to

shortening of the palate, he was stimulated to describe and discuss an operation he had designed in 1869. With a sharp, pointed knife he divided the palate completely from the hamular process (A to B) bilaterally, noting that the parts united in a V-shaped angle. He explained his rationale:

The palate becomes converted into a huge uvula, so to speak . . . so that if it does not actually touch the back of the pharynx it approaches it so nearly as to divert the current of air to a considerable extent from the nose into the mouth, and thus greatly obviate the disagreeable guttural voice.

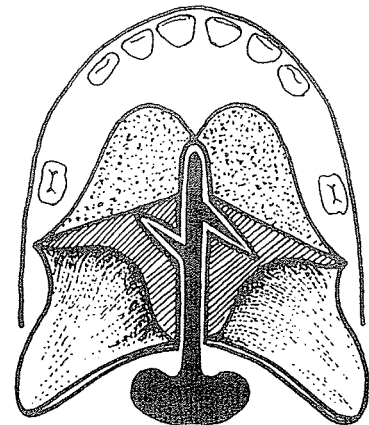


### Z-PLASTY LENGTHENING OF THE SOFT PALATE

In 1950 T. P. Kilner of Oxford suggested obtaining the greatest possible length in the velum by making small incisions at right angles to the pared margins of the cleft or undertaking a Z-plasty of the nasal mucous membrane and, if need be, the palatal mucous membrane.

Randell Champion of Wythenshawe Hospital, Manchester, England wrote in the *British Journal of Plastic Surgery* in 1957:

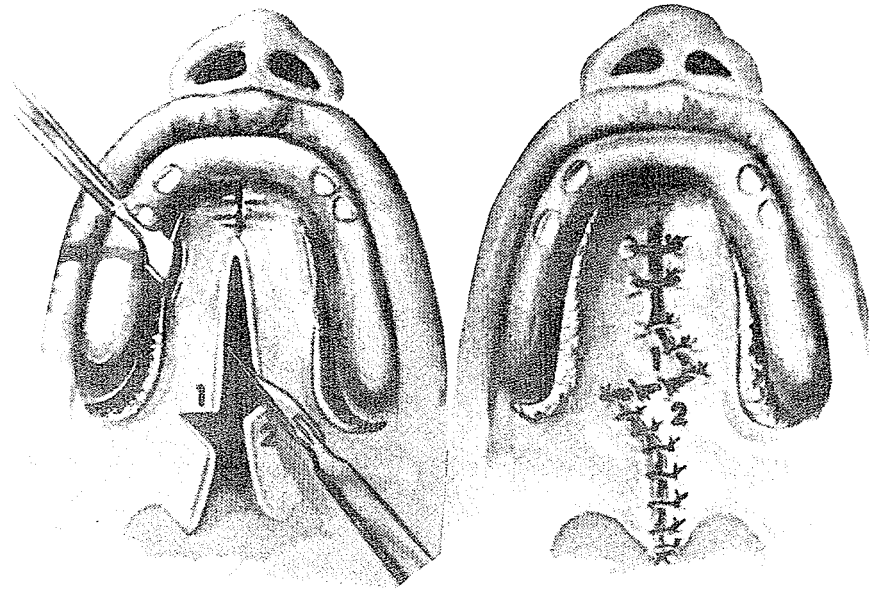
The nasal membrane may be lengthened by undertaking a Z-plasty of the nasal mucous membrane. This small plastic manoeuvre is of utmost importance in the primary repair of a cleft palate and may make the difference between normal and imperfect speech. The Z-plasty also tends to reduce the palato-pharyngeal opening. In a small percentage of primary repairs it is not possible to perform the Z-plasty, particularly in clefts involving most of the hard palate. . . . In secondary repair of palate the creation of a large Z-plasty or two smaller Z-plasties may materially influence the final result.



As Lyndon Peer with Walker and Meijer of New Jersey wrote of the bone flap method in 1964 in *Plastic and Reconstructive Surgery*:

The procedure, however, does not provide for additional lengthening, and if one starts with a short palate, one ends up with a palate of the same length. If the shortening is marked, we lengthen the soft palate with a Z-plasty. . . .

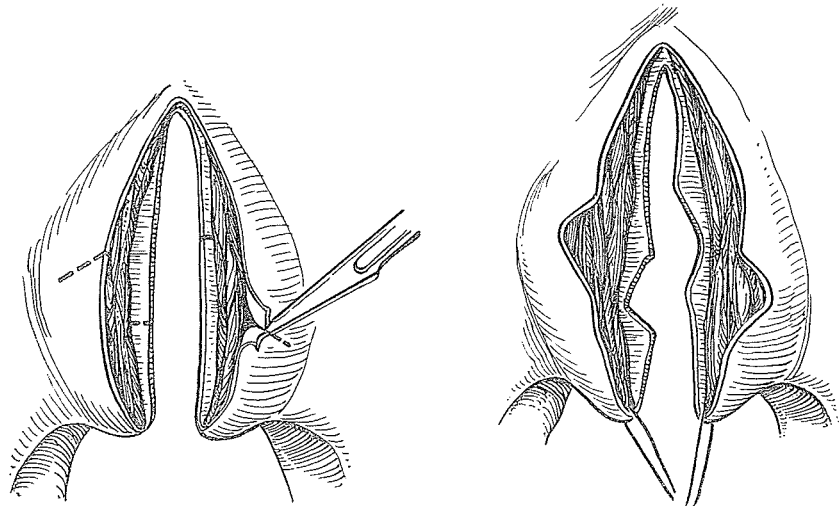
The incisions for this Z-plasty include muscle and both mucous membrane surfaces.



### SCHUCHARDT

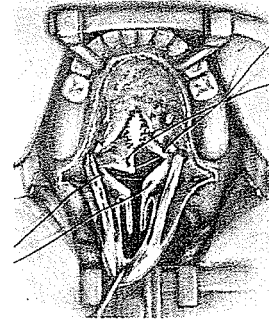
At his Second Hamburg Cleft Palate Symposium in 1964, Karl Schuchardt spoke for improving "old methods." He philosophized before he promoted his own modification:

Besides this I think results do not only depend on methods but also on the way we use them. And I must say that with the old Langenbeck-Ernst-Veau procedure, which is described in the book of Axhausen and which I improved by the lengthening of the velum with a Z-plasty of the mucous membranes of the oral as well as the nasal side, we got such good anatomical shapes and functional results that I see no reason to change our procedure at all.



He spoke from an experience of nearly 1,000 cases.

In 1961 Edgerton facilitated palatal lengthening with sharp dissection of the neurovascular bundles. This resulted in a shortness in the nasal mucosal lining. He advocated the Z-plasty principle as his preference for lengthening this nasal mucosa.



#### A PALATE Z ROBS POOR PETER IN PRINCIPLE

My concern about Z-plasties of the soft palate or nasal lining is basic. The mere presence of a cleft of the palate indicates missing tissue, which may vary in amount, and closure of the cleft necessitates pulling the sides toward the midline with relative tightening in the transverse dimension. This result will be more exaggerated with short, diminutive palates with wide clefts. Too much side-to-side tightness will, of course, counteract the effectiveness of the pushback by pulling against the levator action. The only excuse for using a Z is the longitudinal lengthening of the palate by bilateral transposition of flaps (the sum of the squares of the two sides of a right triangle is equal to the square of the hypotenuse) so that the palate would indeed be extended longitudinally. As in all Z-plasties, however, such lengthening is at the expense of transverse shortening, and if this dimension is already in trouble, as is usually the case, the problem is compounded with an overall loss—instead of a gain!